

## *Histochemical Effects of "Verita WG" on Glycogen and Lipid Storage in Common Carp (*Cyprinus carpio* L.) Liver*

*Elenka Georgieva<sup>1</sup>, Pepa Atanasova<sup>2</sup>, Iliana Velcheva<sup>3</sup>,  
Stela Stoyanova<sup>3\*</sup>, Vesela Yancheva<sup>3</sup>*

<sup>1</sup>Department of Developmental Biology, Faculty of Biology,  
Plovdiv University, 4000 Plovdiv, BULGARIA

<sup>2</sup>Department of Anatomy, Histology and Embryology,  
Medical University of Plovdiv, 4000 Plovdiv, BULGARIA

<sup>3</sup>Department of Ecology and Environmental Conservation, Faculty of Biology,  
Plovdiv University, 4000 Plovdiv, BULGARIA

\* Corresponding author: stela.st@abv.bg

**Abstract.** We aimed in the present work is to study the effects of fosetyl-Al and fenamidone based fungicide ("Verita WG") on glycogen storage and expression of lipid droplets in common carp (*Cyprinus carpio*, L.) liver. Concentrations of the test chemical were 30 mg/L, 38 mg/L and 50 mg/L under laboratory conditions. We used PAS-reaction for detection of glycogen storage and Sudan III staining for detection of lipid droplets in common carp hepatocytes. Hence, we found that the amount of glycogen and the fat storage in the liver increased proportionally with the increased fungicide concentrations. We also found conglomerates of accumulated glycogen in certain hepatocytes at all used concentrations. Overall, the results demonstrated enhanced glycogenesis and fat accumulation in the common carp liver, exposed to the test chemical.

**Key words:** pesticides, histopathology, PAS-reaction, fatty degeneration, liver, common carp

### **Introduction**

Water pollution may be defined as any impairment in its native characteristics by addition of anthropogenic contaminants to the extent that it either cannot serve to humans for drinking purposes and/or to support the biotic communities, such as fish. All water pollution affects organisms that live in these water bodies. It occurs when pollutants are discharged directly or indirectly without adequate treatment to remove the harmful constituents (AGRAWAL *et al.*, 2010). Thus, pesticide contamination of surface waters have been documented worldwide and constitute a major issue that gives rise to concerns at local, regional,

national and global scales (HUBER *et al.*, 2000; CEREJEIRA *et al.*, 2003).

"Verita WG" is a systemic and contact fungicide, effective against plant diseases, caused by fungi of the class *Oomycetes*. The active substances are fosetyl-Al and fenamidone. Fosetyl-Al belongs to the phosphonates, which constitute a relatively new class of systemic fungicides (COHEN & COFFEY, 1986). Fenamidone belongs to the chemical group of imidazolinone and isopropanol, respectively (PEST MANAGEMENT REGULATORY AGENCY, 2003).

Fish are used extensively for environmental monitoring (LANFRANCHI *et al.*, 2006), because they uptake contaminants

directly from the water. Fish liver is rich in antioxidants and plays a major role against toxic compounds which induce free radical production (VAN DYK *et al.*, 2007). Therefore, liver serves as an ideal organ in histopathological studies for different pollutants effects, due to its susceptibility to morphological damage (STENTIFORD *et al.*, 2003; FEIST *et al.*, 2004). Morphological, histological and histopathological alterations related to pesticides presence in the fish liver have been studied, showing that these substances cause a severe damage to the liver cells (KOEHLER, 2004). The main advantage of histochemistry lies in the analysis of biological phenomena in the "particular cells". Histochemical techniques help to analyze not only the localization of lipid and glycogen at cellular level. Histochemical tests reveal the localization of chemical product of cellular activity. Intensity of staining can be used for comparing the lipid and glycogen contents present in the liver cells of the normal fish compared to treated fish with different toxic compounds (PATHAN *et al.*, 2009).

Data from studies carried out on the effects of fenamidone and fosetyl-Al based fungicides on the fish liver are relatively scarce. Therefore, the main objective in the present experiment is to study the histochemical effects of the "Verita WG" on glycogen and lipid storage in common carp (*Cyprinus carpio* L.) liver.

## **Materials and Methods**

### *Test organisms*

Common carp is an economically important fish species, which is widely spread through Europe. It is also used as a bioindicator for estimation of the health of freshwater ecosystems because it is relative insensitive and could survive and accumulate contaminants at heavily contaminated sites (SNYDER *et al.*, 2004; REYNDERS *et al.*, 2008).

Forty healthy common carps were obtained from the "Institute of Fisheries and Aquaculture" in the city of Plovdiv, Bulgaria. They were of the same size-group (mean std. length 16.3 cm  $\pm$  2.7; mean body mass 10.17 g  $\pm$  1.4) with no external

pathological abnormalities. After transportation, the fish were moved in aquaria with chlorine-free tap water (by evaporation) to acclimatize for a week. After acclimatization the fish were divided into four groups (n = 10). Fish were not fed 48 hours before the experiment.

### *Chemicals and experimental setup*

The fungicide "Verita WG" was used in the experiment. It contains the active substance fosetyl-Al (Aluminium tris-O-ethyl phosphonate) 667 g/kg and fenamidone (1-anilino-4-methyl-2-methylthio-4-phenylimidazolin-5-one) 44 g/kg, and it was provided by Bayer CropScience, Germany. Three groups of fish were exposed to fungicide at concentration of 30 mg/L, 38 mg/L and 50 mg/L, representing 50, 40, 30 times dilution of the stock solution, prepared according to the instructions of the manufacturer. The fourth fish group served as a control and the fish were kept in a tank with no added fungicide. The experiment last for 96 h.

All the aquaria had a permanent aeration with air pumps and the water was kept oxygen saturated. For the entire duration of the experiment, the animals were maintained under a natural light/dark cycle (12:12). Water physico-chemical characteristics such as pH, temperature, dissolved oxygen; oxygen saturation, were measured once per day according to a standard procedure (APHA, 2005). They were as follows: pH - 8.2 $\pm$ 0.1; temperature - 24.5 °C  $\pm$  0.12; dissolved oxygen - 7.26 mg/L  $\pm$  0.2; oxygen saturation - 90.25%  $\pm$  3.3.

### *Histochemical analysis*

Fish dissection was performed according to the international standard procedures given in the EMERGE Protocol (ROSSELAND *et al.*, 2003).

Histochemical analysis was carried out in the laboratory at the Department of Anatomy, Histology and Embryology at Medical University of Plovdiv, Bulgaria. Cryostat (Leica, Jung Frigocut 2800 N) was used to cut the samples. Multiple carp liver sections (6  $\mu$ m) of each specimen were prepared according to standard

methodology. Liver samples were also stained with Sudan III according to Daddy and by the PAS method according to McManus. All used histochemical techniques are described by PEARSE (1968, 1972)

Experimental set up was conducted in accordance with national and international guidelines of the European Parliament and the Council on the protection of animals used for scientific purpose (DIRECTIVE 2010/63/EU).

Liver histochemical alterations of all specimens, including control fish livers were appraised individually and semi-quantitatively by using the grading system. Positive PAS-reaction was presented in purple-magenta staining and positive Sudan III staining was expressed with small yellow and large orange fat droplets in hepatocytes cytoplasm. Evaluation of the histopathological changes was carried out and presented as an average value. Each grade represents specific histochemical characteristics and is categorized as follows: (-) - negative reaction of histochemical staining; (+/-) - very weak positive reaction of histochemical staining; (+) - weak positive reaction of histochemical staining; (++) - moderate positive reaction of histochemical staining; (+++) - strong positive reaction of histochemical staining in the hepatocytes.

## **Results**

### *Intensity of PAS-reaction*

We observed in the control fish liver positive PAS-reaction in separate areas of liver parenchyma (Fig. 1a). Intensity of the PAS-reaction was increased in direct proportion with the increase of the pesticide concentration, which was indicative of an increase in the glycogen amount in hepatocytes (Table 1).

We found a tendency towards an increased intensity of PAS-positive grain-like structures, which varied from fine to large grains in the three experimental fish groups, which suggests an increase in the

amount of accumulated glycogen in hepatocytes.

There was an increase of PAS-reaction in all cryosections of fish, exposed to 30 mg/L pesticide, i.e. more-intense purple-magenta staining compared with the control group (Fig. 1b). Intensity of PAS-reaction was moderate. This suggests an increase in the amount of glycogen compared the control group.

We also detected moderate PAS-positive staining in the investigated fish, exposed to 38 mg/L concentration of pesticide. This indicates that the accumulation of glycogen in the hepatocytes was similarly to the test group, exposed to 30 mg/L pesticide (Fig. 1c).

Furthermore, we observed strong positive PAS-reaction in the fish group (Fig. 1d), which were exposed to the highest fungicide concentration (50 mg/L). Thus, more intense PAS-reaction demonstrated the highest amount of glycogen in the common carp liver.

Lastly, we detected conglomerates of accumulated glycogen in certain hepatocytes from all test fish groups (Table 2). Amount of the conglomerates was increased proportionally to the fungicide concentration. At the lowest concentration (30 mg/L) we determined conglomerates of accumulated glycogen in single hepatocytes (+/-). In fish liver from the test groups, exposed to 38 mg/L conglomerates were present in more hepatocytes (+) and respectively, the most pronounced presence of glycogen conglomerates was in the fish, exposed at concentration of 50 mg/L (++) . We did not find conglomerates of accumulated glycogen in the hepatocytes from the control group.

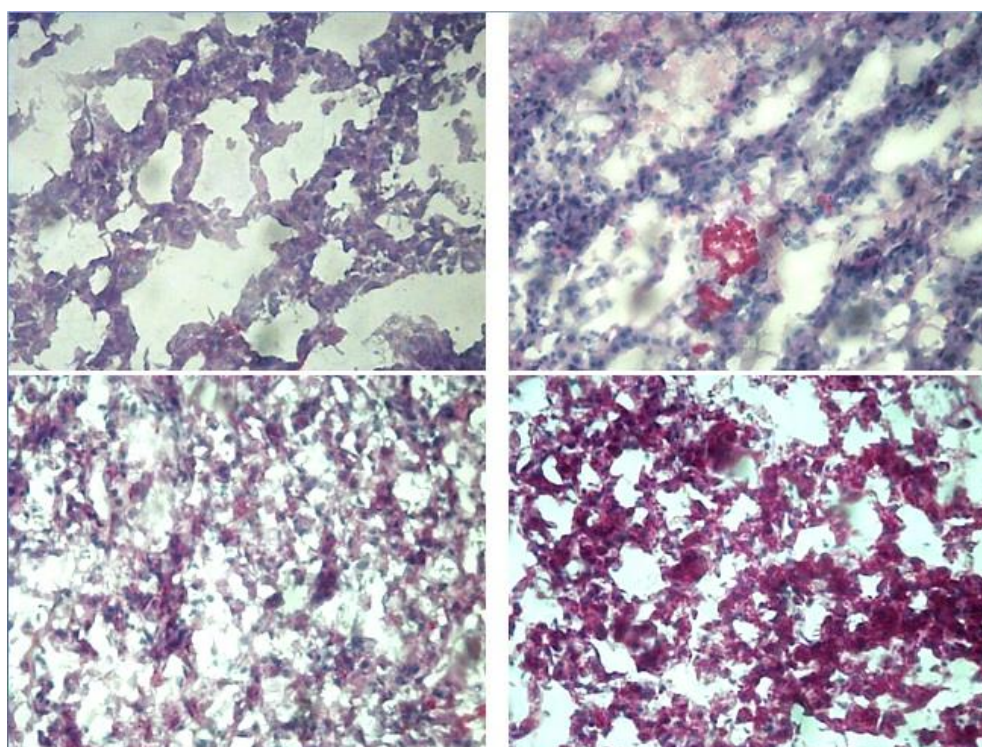
### *Intensity of Sudan III staining*

We found very weak positive reaction of Sudan III staining in control fish group. Intensity of Sudan III staining from all test groups increased with the increased concentrations of the test fungicide (Table 3).

**Table 1.** Intensity of PAS-reaction

Concentration of the fungicide	Control group	30 mg/L	38 mg/L	50 mg/L
Intensity of PAS- reaction staining	+	++	++	+++

(-) - negative reaction of histochemical staining; (+/-) - very weak positive reaction of histochemical staining; (+) - weak positive reaction of histochemical staining; (++) - moderate positive reaction of histochemical staining; (+++) - strong positive reaction of histochemical staining in the hepatocytes



**Fig. 1.** Intensity of PAS-reaction in common carp liver. **a** - The intensity of PAS-reaction in control fish group, x200; **b** - The intensity of PAS-reaction and conglomerates of accumulated glycogen at concentration 30 mg/L fungicide, x200; **c** - The intensity of PAS-reaction and conglomerates of accumulated glycogen at concentration 38mg/L fungicide, x200; **d** - The intensity of PAS-reaction and conglomerates of accumulated glycogen at concentration 50 mg/L fungicide, x400.

**Table 2.** Conglomerates of accumulated glycogen in common carp liver.

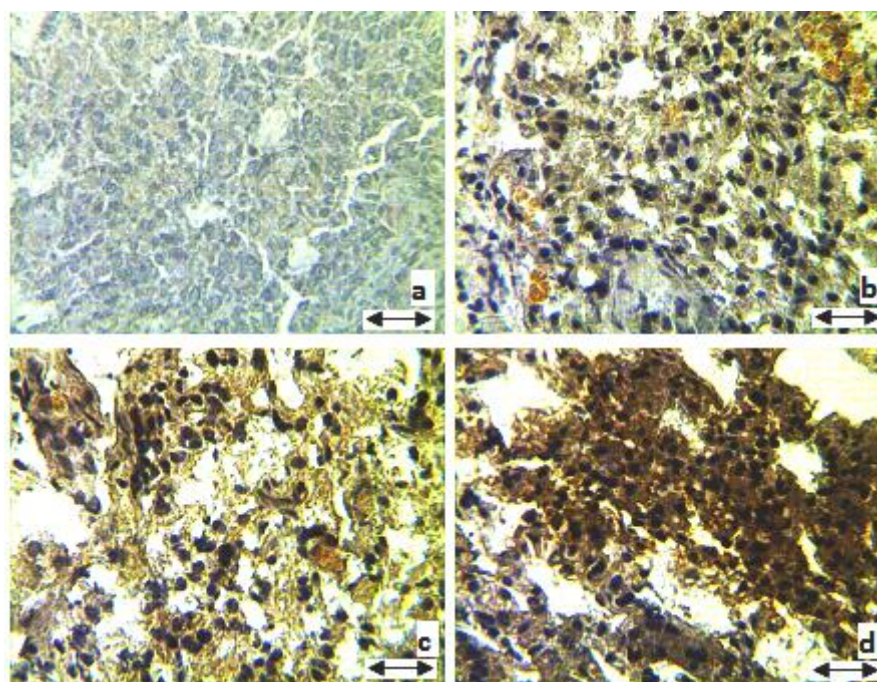
Concentration of the pesticide	Control group	30 mg/L	38 mg/L	50 mg/L
Amount of glycogen conglomerates	-	+/-	+	++

(-) - negative reaction of histochemical staining; (+/-) - very weak positive reaction of histochemical staining; (+) - weak positive reaction of histochemical staining; (++) - moderate positive reaction of histochemical staining; (+++) - strong positive reaction of histochemical staining in the hepatocytes

**Table 3.** Intensity of Sudan III staining

Concentration of the pesticide	Control group	30 mg/L	38 mg/L	50 mg/L
Intensity of Sudan III staining	±	+	++	+++

(-) - negative reaction of histochemical staining; (+/-) - very weak positive reaction of histochemical staining; (+) - weak positive reaction of histochemical staining; (++) - moderate positive reaction of histochemical staining; (+++) - strong positive reaction of histochemical staining in the hepatocytes



**Fig. 2.** Intensity of Sudan III staining in common carp liver, x 400. **a** - Control group; **b** - Intensity of staining and Sudan positive fat vacuoles at concentration 30 mg/L fungicide; **c** - Intensity of Sudan III staining at concentration 38 mg/L fungicide; **d** - Intensity of Sudan III staining at concentration 50 mg/L fungicide.

We observed in the control group in separate sections in the hepatocytes very weak yellow staining of Sudan III (Fig. 2a). Intensity of staining of the liver parenchyma of all specimens, exposed to the lowest concentration (30 mg/L) was weak (more intense yellow staining). Also, we found a slight increase of lipid droplets in the hepatocyte cytoplasm (Figure 2b). Moreover, we observed in the fish group, exposed to 38 mg/L of the test pesticide more pronounced lipid droplets in the hepatocytes, which were stained in yellow-orange (Fig. 2c). We found strong positive Sudan III staining at the highest pesticide concentration (50 mg/L), which indicates the increase of fat deposits in the cytoplasm

(Fig. 2d). Lipid droplets were stained in orange.

### Discussion

Our results indicate an increase in the amount of glycogen in the liver parenchyma. Similar to us FRANCHINI *et al.* (1991) found lipid accumulation in fish liver, which suggests changes in the liver function under the effluence of different toxicants. Other authors reported that exposure of subchronic doses of pesticides inhibit glycogenolysis and promote glyconeogenesis (SINGH *et al.*, 1996). SPISNI *et al.* (1998) observed hepatic fat deposition. The authors described a disturbance resulting from an excessive or unbalanced

supply of dietary lipids which exceeds the physiological lipid conversion ability of liver, resulting in hepatic lipid accumulation as fat drops (triglycerides).

REZG *et al.* (2006, 2007) concluded that under the effect of subchronic dose of organophosphate insecticide malathion, the storage of glycogen in rat liver may be due to a stimulation of insulin secretion after the inhibition of acetylcholinesterase activity in pancreatic beta cells. These studies indicate that hyperglycemia is temporary, which is probably due to a stimulated glycogenesis that increases hepatic glycogen deposition in liver. The authors suggest that these results are due to the turnover of glucose by a succession between its release, glycogenolysis and glycogenesis, which involves abnormal hyperglycemia, and its storage via glycogenesis in subchronic exposure to pesticide.

It is clear that other authors found in their studies increased amount of glycogen in the liver of different test species under the influence of many toxicants. We also found an increase in the amount of glycogen in the liver parenchyma. However, it would be difficult to comment in detail the mechanism for this accumulation. We, therefore, can only say that our results show that the changes in the common carp liver metabolism under the influence of the studied fungicide were expressed mainly in accelerating the process of glycogenesis and accumulation of lipids. In addition, intensity of accumulation of glycogen and lipids in the carp liver is proportional with the chemical concentrations.

### **Conclusion**

Overall, we investigated an increase the intensity of PAS-reaction and accumulation of lipid droplets in fish liver, which correlates with the increasing concentration of the fungicide. We can conclude that the increase of the amount of glycogen and lipid droplets in the hepatocytes suggests a process of transforming the accumulated glycogen in fat (lipids). Moreover, we can associate this process with induced glycogenesis. Therefore, this could be

considered a series of compensatory mechanisms in fish and liver metabolism in response to the toxic effects of pesticides and the stress they induce. Further investigations in this particular area need to be carried out to better understand the metabolic changes in the liver under the influence of organic contaminants.

### **References**

- AGRAWAL A., R.S. PANDEY, B. SHARMA. 2010. Water Pollution with Special Reference to Pesticide. - *Journal of Water Resource and Protection*, 2: 432-448.
- APHA. 2005. Standard methods for examination of water and wastewater, 21<sup>st</sup> Ed. - *American Public Health Association, Washington, DC*.
- CEREJEIRA M.J., P. VIANA, S. BATISTA, T. PEREIRA, E. SILVA, M.J. VALERIO, A. SILVA, M. FERREIRA, A.M. SILVA-FERNANDES. 2003. Pesticides in Portuguese surface and ground waters. - *Water Research*, 37: 1055-1063.
- COHEN Y., M.D. COFFEY. 1986. Systemic fungicides and the control of *Oomycetes*. - *Annual Review of Phytopathology*, 24: 311-338.
- DIRECTIVE 2010/63/EU of the European Parliament and of the Council on the protection of animals used for scientific purposes. - *Official Journal of the European Union*.
- FEIST S.W., T. LANG, G.D. STENTIFORD, A. KÖHLER. 2004. The use of liver pathology of the European flatfish, dab (*Limanda limanda*, L.) and flounder (*Platichthys flesus*, L.) for monitoring biological effects of contaminants. - *Techniques in Marine Environmental Sciences*, 38: 1-42.
- FRANCHINI A., E. BARBANTI, A.M. FANTIN. 1991. Effects of lead on hepatocyte ultrastructure in *Carassius carassius* (L.) var. *Auratus*. - *Tissue and Cell*, 23(6): 893-901.
- HUBER A., M. BACH, H.G. Frede. 2000. Pollution of surface waters with pesticides in Germany: modeling

- non-point source inputs. - *Agriculture, Ecosystems & Environment*, 80: 191-204.
- KOEHLER A. 2004. The gender-specific risk to liver toxicity and cancer of flounder (*Platichthys flesus* (L.)) at the German Wadden Sea coast. - *Aquatic Toxicology*, 70: 257-276.
- LANFRANCHI A.L., M.L. MENONE, K.S.B. MIGLIORANZA, L.J. JANIOT, J.E. AIZPUN, V.J. MORENO. 2006. Striped weakfish (*Cynoscion guatucupa*): a biomonitor of organochlorine pesticides in estuarine and near-coastal zones. - *Marine Pollution Bulletin*, 52: 74-80.
- PATHAN T.S., P.B. THETE, S.E. SHINDE, D.L. SONAWANE, Y.K. KHILLARE. 2009. Short Communication Histochemical changes in the liver of freshwater fish, *Rasbora daniconius*, exposed to paper mill effluent. - *Emirates Journal of Food and Agriculture*, 21(2): 71-78.
- PEARSE A.G.E. 1968. *Histochemistry: Theoretical and Applied*. Vol. 1. 3<sup>rd</sup> Edition. J & A Churchill. London. 759 p.
- PEARSE A.G.E. 1972. *Histochemistry: Theoretical and Applied*. Vol. 2 3<sup>rd</sup> Edition. Churchill-Livingstone. London. 1518 p.
- PEST MANAGEMENT REGULATORY AGENCY. 2003. Pyraclostrobin Headline EC Cabrio EG, Health. Canada. 106 p.
- REYNDERS H., L. BERVOETS, M. GELDERS, W.M. DE COEN, R. BLUST. 2008. Accumulation and effects of metals in caged carp and resident roach along a metal pollution gradient in Flanders. - *Belgium Science of the Total Environment*, 391: 82-95.
- REZG R., B. MORNAGUI, M. EL-ARBI, A. KAMOUN, S. EL-FAZAA, N. GHARBI. 2006. Effect of subchronic exposure to malathion on glycogen phosphorylase and hexokinase activities in rat liver using native PAGE. - *Toxicology*, 1: 9-14.
- REZG R., B. MORNAGUI, A. KAMOUN, S. EL-FAZAA, N. GHARBI. 2007. Effect of subchronic exposure to malathion on metabolic parameters in the rat. - *Comptes Rendus Biologie*, 330(2): 143-147.
- ROSSELAND B.O., J.C. MASSABUAU, J. GRIMALT, R. HOFER, R. LACKNER, G. RADDUM, S. ROGNERUD, I. VIVES. 2003. Fish ecotoxicology: European mountain lake ecosystems regionalisation, diagnostic and socio-economic evaluation (EMERGE). Fish sampling manual for live fish, Norwegian Institute for Water Research (NIVA). Oslo, Norway. 7 p.
- SINGH N.N., V.K. DAS, S. SINGH. 1996. Effect of aldrin on carbohydrate, protein and ionic metabolism of freshwater catfish, *Heteropneustes fossilis*. - *Bulletin of Environmental Contamination and Toxicology*, 57: 204-210.
- SNYDER E.M., S.A. SNYDER, K.L. KELLY, T.S. GROSS, D.L. VILLENEUVE, S.D. FITZGERALD. 2004. Reproductive responses of common carp (*Cyprinus carpio*) exposed in cages to influent of the Las Vegas Wash in Lake Mead, Nevada, from late winter to early spring. - *Environmental Science and Technology*, 38: 6385-6395.
- SPISNI E., M. TUGNOLI, A. PONTICELLI, T. MORDENTI, V. TOMASI. 1998. Hepatic steatosis in artificially fed marine teleosts. - *Journal of Fish Diseases*, 21: 177-184.
- STENTIFORD G.D., M. LONGSHAW, B.P. LYONS, G.J. JONES, M. GREEN, S.W. FEIST. 2003. Histopathological biomarkers in estuarine fish species for the assessment of biological effects of contaminants. - *Marine Environmental Research*, 55(2): 137-159.
- VAN DYK J.C., G.M. PIETERSE, J.H.J. VAN VUREN. 2007. Histological changes in the liver of *Oreochromis mossambicus* (Cichlidae) after exposure to cadmium and zinc. - *Ecotoxicology and Environmental Safety*, 66: 432-440.

Received: 14.11.2013

Accepted: 20.13.2013